

Outcome Analysis of the Treatment of Posterior Brachycephaly with Prefabricated Helmet Therapy

C. SANGER, A. ARGENTA, J. SIMPSON, L. DAVID and L. ARGENTA

Plastic and Reconstructive Surgery Department, Wake Forest University Medical Center, Winston-Salem, NC, USA

SUMMARY

The dramatic increase of cranial asymmetry in otherwise healthy infants has been established during the past decade. Central positional deformities, or posterior brachiocephaly, are a minority of these patients but their deformities may be the most difficult to treat. Children diagnosed at our institution with posterior brachycephaly are treated with a prefabricated helmet that can be adjusted for the individual child. In some cases a removable block was placed on the external central helmet that prevents the child from lying on that part of the skull. The helmet then becomes a positioning device as well as a molding device. We present our experience with posterior brachycephaly treated with an off the shelf, prefabricated helmet.

INTRODUCTION

The incidence of positional cranial deformities in otherwise healthy infants has increased dramatically during the past decade. Following the recommendations of the American Academy of Pediatrics in 1992 that infants be placed on their back to reduce the incidence of Sudden Infant Death Syndrome (SIDS), the vast majority of patients in the western world now sleep in the supine position. Most affected infants lie preferentially on one side or the other, resulting in the classic parallelogram shape of the positional plagiocephaly deformity. Approximately 20% of infants lie directly in the supine position, preferring neither side and develop central positional plagiocephaly or positional brachycephaly. The amount of time spent in such a position results in three degrees of progressive severity of the central deformity as we have previously described.¹ There is little available literature regarding central brachycephaly and the deformity is only mentioned anecdotally in most publications. Some craniofacial surgeons feel that the deformity can only be improved and not totally corrected². It has been postulated that the increased bone mass of the cranial base and the paucity of sutures makes it more resistant to molding than the cranial vault.

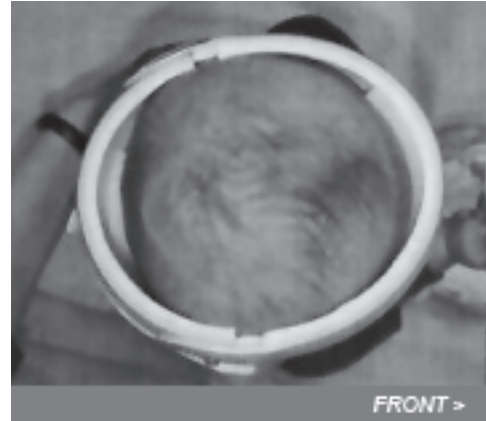


Figure 1. Vertex view of a child with posterior brachycephaly in a molding helmet with space on the posterior aspect of the helmet into which the expanding brain will push the skull. Deformation laterally is precluded by minimal force exerted by the helmet.

There are presently two methods of treating positional deformities- repositioning or molding helmet therapy. Repositioning can take many forms including sand bags, towel rolls, foam wedges and repositioning at two hour intervals. All of these are designed to prevent the child from lying on the flattened central occiput. The central depressed area of the skull in these children, however, is usually so broad that it is difficult for the child to be positioned laterally.

The most widely available molding helmets are custom fabricated devices that wrap around the cranial vault and exert pressure preferentially over prominent areas of the skull, thus altering cranial growth patterns. These devices incur considerable expense, usually in the range of \$3000 per helmet, and require alterations at regular intervals by a specially trained orthotist.

Over the past 5 years, we have employed a commercially available, prefabricated, adjustable, off the shelf helmet for the treatment of children with posterior brachycephaly and posterior plagiocephaly [ASEMT, Lewisville, N.C., U.S.A.].³ These helmets avoid the need for custom fabrication, can be expanded as the child grows and



Figure 2. A removable foam block can be attached centrally to the helmet. The child reclining will then roll off the block to the right or to the left. This allows control over positioning and molding of the skull.

cost approximately \$500 (Figure 1). The helmet is not a constricting device, but allows the patient's growing skull to preferentially grow into a prefabricated template of a normal skull. In addition, we use an external foam block on the helmet which inhibits the child from lying on that particular portion of the skull (Figure 2). The addition of the external foam block placed centrally over the occipital brachycephaly, requires the child to sleep on either one side of the skull or the other. Such a helmet then becomes not only a molding device, but a positioning device as well.

MATERIALS AND METHODS

Outcome analysis of patients in our IRB approved study for the treatment of deformational posterior brachycephaly with the previously described helmets includes 75 patients from 2000 to 2004. There were 60 males and 15 females in the study group. Average age at enrollment in the study was 5.67 months. All children were seen at two month intervals until the calvarial shape was felt to be normal. Physical examination using our clinical classification system (Figure 3) as well as 3-D computer scans [Polhemus, Colchester, Vt.; Fairfield Technology, New Zealand] was used to grade the calvarial correction during therapy.

RESULTS

Sixty seven of the 75 patients treated achieved normal cranial shape and symmetry. Eight patients retained observable central flattening at the end of treatment. Treatment termination before achieving a complete resolution was because of parent wishes. Clinical examination and 3-dimensional imaging scans correlated extremely well for follow-up evaluation of the study

children (Figure 4). In addition, quantitative evaluation of the degree of asymmetry, as calculated by standard cranial quadrant volume blocks generated from the 3-D computer scans revealed that deformational brachycephaly children could be normalized as well as children with standard positional plagiocephaly (Figure 5 & 6). These children demonstrated a return to symmetry after an average of 4.6 months of treatment. Children who began therapy at or before 6 months of age corrected more rapidly (4.1 months).

Compliance with wearing the helmet determined both from parental reports as well as clinical evaluation of the helmet for wear and tear was also significant. Children who wore the helmet 20 to 24 hours a day responded more completely and in a more rapid fashion than children whose compliance was judged less than optimal. Significantly, children over the age of 12 months were able to remove the helmet and parents had considerable more difficulty maintaining treatment.

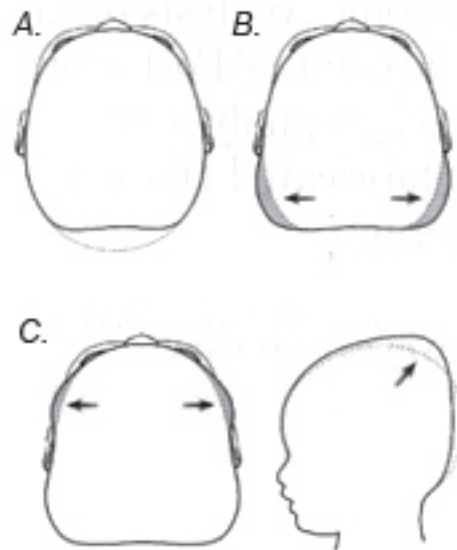


Figure 3. Three stages of progressively severe posterior brachycephaly:

- A) Posterior central flattening of the skull without compensatory lateral bulging;*
- B) With progressive flattening of the skull over a protracted period of time, the brain seeks to decompress by pushing the occipital bones laterally.*
- C) The increasing pressure of the growing brain against the constrained posterior growth of the skull, results in bulging of the temporal fossa where the bone is thin as well as vertical growth of the posterior occiput.*

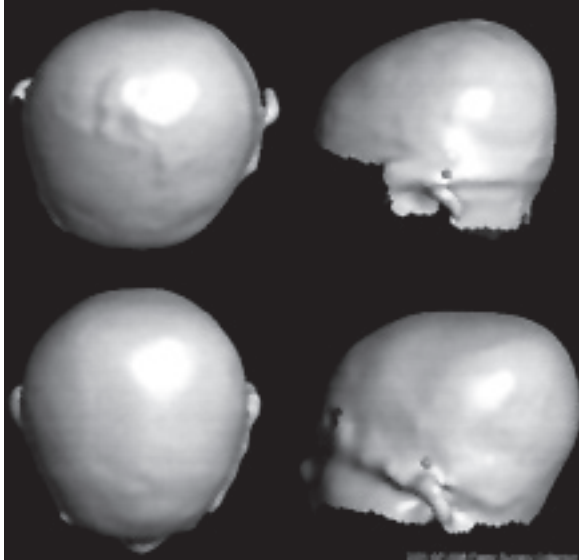


Figure 4. Three-dimensional imaging achieved with the Polhemus laser scanner and Fairfield Technology software, demonstrating the vertex and side view of a child with deformational brachycephaly demonstrating the posterior flattening with an increase in vertical growth prior to treatment and four months after treatment with one of our helmets.

As treatment progressed, the central deformity remolded into the prefabricated helmet. The vertical distortion of the posterior skull in more advanced cases slowly became less obvious as the skull developed posteriorly. The temporal bulging seen in some of the more advanced cases of posterior brachycephaly did not resolve.

CONCLUSION

Successful treatment of posterior brachycephaly can be accomplished with prefabricated adjustable helmets which function both as positioning and molding devices. The cost of treatment can be minimized making therapy available to all children. The need for custom helmet fabrication and multiple return visits is obviated. With appropriate compliance, children with positional posterior brachycephaly can be successfully treated at minimum cost.

Correction can usually be accomplished within 5 months, depending on compliance. Correction is accomplished more rapidly in children when treatment begins under 6 months of age. Children treated after 6 months of age remain correctable, but require longer therapy.

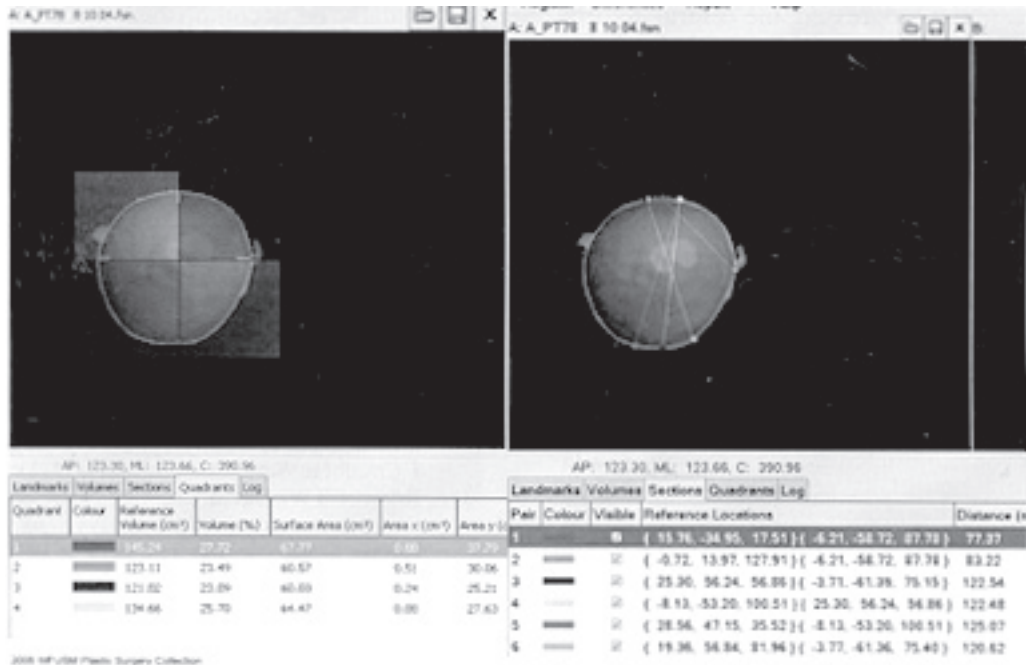


Figure 5. Pre-treatment 3D scan with the Polhemus laser scanner and FarField Technology software, demonstrating the quadrants with obvious asymmetry.

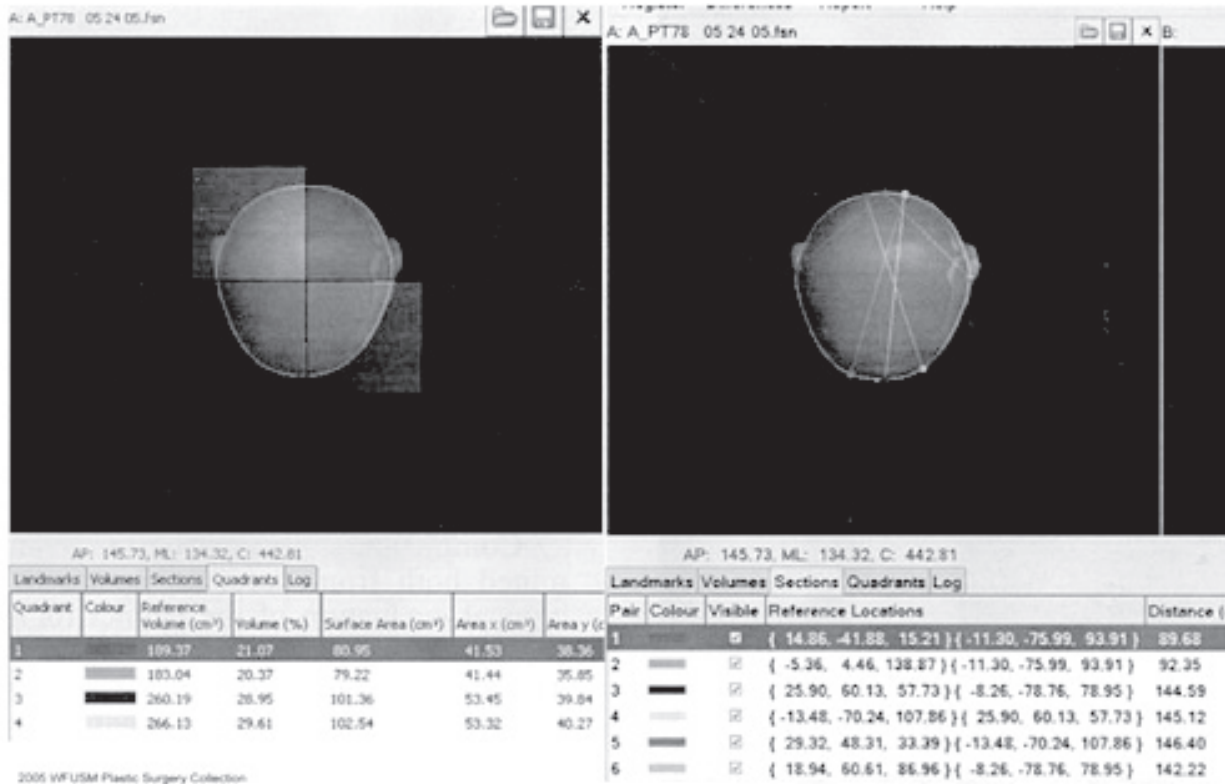


Figure 6. Post-treatment 3D scan with the Polhemus laser scanner and FarField Technology software, demonstrating the quadrants with correction of the pre-treatment asymmetry and normalization of volumes.

REFERENCES

1. Argenta LC, David LR, Thompson J. Clinical classification of positional plagiocephaly. *J Craniofac Surg.* 2004 May 15(3):368-72.
2. Teichgraeber JF, Seymour-Dempsey K, Baumgartner JE, et al. Molding helmet therapy in the treatment of brachycephaly and plagiocephaly. *J Craniofac Surg.* 2004 January 15(1):118-23.
3. Brunner 1W, David LR, Gage HD, Argenta LC. Objective outcome and analysis of soft shell helmet therapy in the treatment of deformational plagiocephaly. *J Craniofac Surg.* 2004 July 15 (4):643-50.

This paper was published in:
 CRANIOFACIAL SURGERY 11: Proceedings of the Eleventh International Congress of
 The International Society Of Craniofacial Surgery
 Coolum, Queensland, Australia, 2005
 Medimond International Proceedings, Bologna, Italy